



TANTIA UNIVERSITY JOURNAL OF HOMOEOPATHY AND MEDICAL SCIENCE

www.tjhms.com

CASE REPORT

EFFECTIVENESS OF HOMOEOPATHIC MEDICINE IN TREATMENT OF WARTS- A CASE STUDY

Neha Nagar¹, Ravi Kumar Poswal², Ajay Kumar³

¹Department of Repertory, ²Department of Materia Medica, ³Department of Paediatrics – Bakson Homoeopathic Medical College & Hospital, Greater Noida.

Abstract

Received- 15/05/2023

Revised- 20/06/2023

Accepted- 25/06/2023

Key Word- Homoeopathy,
Warts, HPV ,
Cauterization,

Corresponding Author:-

Neha Nagar, Department of Repertory, Ravi Kumar Poswal, Department of Materia Medica, Ajay Kumar, Department of Paediatrics, Bakson Homoeopathic Medical College & Hospital, Greater Noida.

Warts are benign tumors caused by DNA viruses' i.e. Human papilloma viruses. Overall prevalence is known to be around 7-10% of the population. It is essential to get rid of the disease as soon as possible because the affected person suffers from cosmetic disfigurement with pain and remains as a potent source of transmission to others leading patients to go for drastic measures such as cauterization and various oils and ointments costing them a huge sum, homoeopathic drugs, on the other hand are cost effective and easy to take having no side effect. Homoeopathy has a major role in treatment of warts. A male patient was reported in OPD of Bakson Homoeopathic Medical College & Hospital, after detail case taking and after repertorization & on the basis of individualization, *Lycopodium clavatum* was given, this article is to show effectiveness of homeopathic medicine.

INTRODUCTION

Warts are skin growths caused by human papillomavirus (HPV) infection. HPV is a DNA virus that has not been cultured *in vitro*.

There are three types of warts:

- Common warts appear on any part of the body
- Plantar warts appear on the soles of feet
- Genital and anal warts appear on the genitalia and anal regions, respectively.

Various treatment procedures are available for removing warts, such as:

- Applying salicylic acid, liquid nitrogen, and podophyllin
- Loop electrosurgical excision procedure
- CO2 laser surgery
- Interferon injections.¹

The diagnosis is based on clinical examination and usually straight forward by visual inspection. Indications for treatment include pain, interference with function, cosmetic embarrassment and risk of malignancy.²

Clinically, three types of warts are encountered in dermatology practice –common warts, plantar warts and genital/anal warts. They may be soft, hard, rough, smooth, scaly, flat etc. Which are mainly determined by the type of the virus and the location.

CASE STUDY

A 25-year-old male reported to the OPD of Bakson Homoeopathic Medical College & Hospital, on 18 October 2022 with bleeding warts on both cheeks & beard area since 1.5 years, with gas formation in upper abdomen. No other chief complaints were noted. His appetite was decreased (1–2 *chapatis*, 3 meals/day) and had a desire for sweets, aversion to oily food and extreme thirst for large quantities of water. His perspiration was too offensive. He had repeated dreams of dead relatives. He easily got offended on small things, he always find fault in everywhere he clearly said that everyone says you have bad habit of it, want everything in arranged manner even at work place also.

Very emotional by nature. Hot patient. The patient did not suffer from any other major illness in the past, except from some gastric disturbances. Family history was not significant.

The patient was a Government employee belonging to a middle-class socioeconomic group.

ANALYSIS OF CASE:

MENTAL GENERAL:

- Sentimental (Emotional).
- Offended easily.
- Want everything in arranged manner even at work place also.

- He always find fault in everywhere he clearly said that everyone says you have bad habit of it .

PHYSICAL GENERAL:

- Thirst – for large quantity of water
- Thermal – Hot.
- Desire – sweets.
- Aversion- oily food.
- Perspiration- Offensive.
- Dreams – of dead relatives.

PARTICULARS:

- Bleeding warts on face (beard & cheeks).

EVALUATION:

- Sentimental (Emotional). .
- Offended easily.
- Want everything in arranged manner even at work place also
- He always find fault in everywhere he clearly said that everyone says you have bad habit of it
- Dreams – of dead relatives.
- Thirsty - Extreme thirst for large quantity of water

After framing the totality following symptoms were converted into rubrics. As follows

S.NO	Symptoms	Rubrics
1	Sentimental (Emotional).	Sentimental
2	Offended easily.	Offended easily
3	Want everything in arranged manner even at work place also	fastidious
4	He always find fault in everywhere he clearly said	Censorious critical

- Desire -for sweets
- Hot patient.
- Aversion – oily food.
- Sweat- Odor offensive.
- Bleeding wart on face (beard & cheeks).

TOTALITY OF SYMPTOMS:

- Sentimental (Emotional).
- Offended easily.
- Want everything in arranged manner even at work place also
- He always find fault in everywhere he clearly said that everyone says you have bad habit of it.
- Dreams – of dead relatives.
- Thirsty – Extreme thirst for large quantity of water
- Desire -for sweets
- Hot patient
- Aversion – oily food.
- Sweat- Odor offensive.
- Bleeding warts on face (beard & cheeks).

	that everyone says you have bad habit of it	
5	Dreams – of dead relatives.	Dreams-Death-Relative
6	Thirsty – Extreme thirst for large quantity of water	Stomach-large-quantity
7	Desire for sweets	Stomach -Desire-sweets
8	Aversion – oily food.	Stomach-Aversion to oily food
9	Sweat- Odor offensive.	Perspiration-odor-offensive
10	Bleeding warts on face (beard & cheeks).	Skin-Wart-Bleeding

Miasmatic evaluation for the presenting symptoms was done with the help of ‘The Chronic disease by Dr. Samuel Hahnemann’ showed the predominance of Sycotic miasm. Considering the above symptomatology, synthesis Repertory was preferred and using Radar opus software, systemic repertorization was done.

The Repertorization chart is given in [Fig-1].

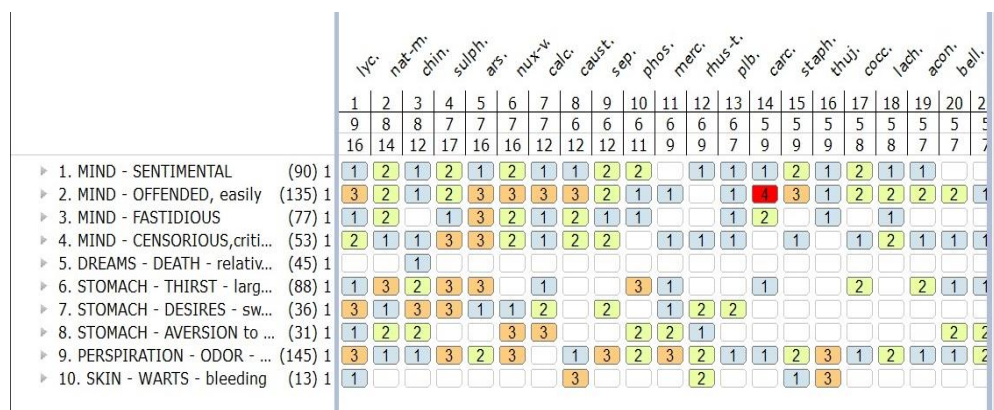


Fig-1

PDF SYMPTOM- Hot Patient

Lycopodium clavatum 200 in single dose followed by Placebo 200 TDS for 15 days was prescribed on first visit (18/10/2022) considering the reportorial totality and miasmatic background. The patient improved symptomatically.

FOLLOW UP

Follow-up Date	Indication of Prescription	Medicine with Dose
03/11/22	No apparent change was seen in the lesions. Bleeding while shaving Occurred once last week.	Placebo 200 for 1 month
4/12/22	Lesions drying up. Appearing smaller in size.	Placebo 200 for 15 Days
19/12/22	Smaller lesions have dried up and a 2-3 disappeared, but no apparent Changes in a few lesions.	Placebo 200 for 15 Days
20/01/23	Lesions completely resolute, the beard area looks clean now.	Placebo 200 for 1 month

RESULT

There is marked improvement in bleeding warts. *Lycopodium clavatum 200* 1 dose orally followed by placebo showed improvement. warts completely disappeared within a period of 3 months of homoeopathic treatment [Figure 1] Before Treatment, [Figure 2] After Treatment

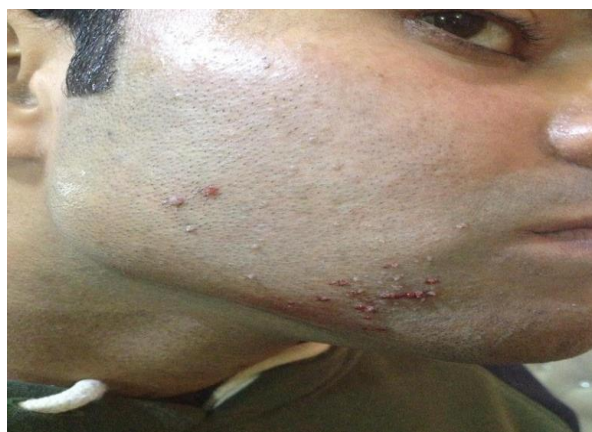
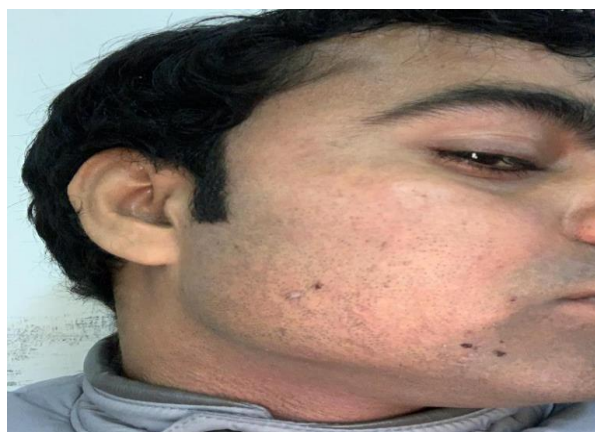
Fig-2 BEFORE TREATMENT



AFTER TREATMENT

DISCUSSION AND CONCLUSION

Homoeopathy treats the person as a whole mentally as well as physically also. In this case important mental generals and physical generals are were included for repertorization purpose.

After repertorization, many medicines were competing which each other, namely, *Lycopodium clavatum*, *Natrum muraticum*, *Chin*, *Sulphur*, *Arsenic album*, *Nux vomica*, etc. but after consultation with *Materia Medica*,

Lycopodium clavatum was prescribed which remained unchanged in the subsequent follow-ups as the patient was responding well to the medicine.

REFERENCES

1. Sterling JC, Handfield-Jones S, Hudson PM, British Association of Dermatologists. Guidelines for the management of cutaneous warts. Br J Dermatol. 2001;144:4-11. [CrossRef] [PubMed] [Google Scholar]
2. Sekhar Namburi U, Babu G, Omprakash. A review on management of warts in Ayurveda. AYU (An International Quarterly Journal of Research in Ayurveda) 201132(1):100.
3. Khanna N. Illustrated synopsis of dermatology & sexually transmitted diseases. 5th ed. Reed Elsevier Pvt. Ltd, New Delhi. 2016. P-29
4. Radar Opus Homeopathic Software
5. Hahnemann S. The Chronic Diseases Their Peculiar Nature and Their Homoeopathic Cure. Low Price Edition. New Delhi: B. Jain Publishers Pvt. Ltd.; 2002. p. 46, 61-2.
6. Boericke W. Pocket Manual of Homoeopathic Materia Medica and Repertory. 9th Reprint ed. New Delhi: B Jain Publishers; 2007.

How to Cite this Article- Nagar N., Poswal R. K., Kumar A., Effectiveness Of Homoeopathic Medicine In Treatment Of Warts- A Case Study. TUJ. Homo & Medi. Sci. 2023;6(2):59-64.

Conflict of Interest: None

Source of Support: Nil

